

# Toward computer-assisted diagnosis and telemedicine in ophthalmology

Andrés G. Marrugo, María S. Millán, Gabriel Cristóbal, Salvador Gabarda, Michal Šorel, and Filip Šroubek

*Recent developments in retinal image analysis enable the possibility of advanced computerized medical systems.*

Digital retinal imaging is an important element of modern ophthalmology. It provides visual documentation and, most importantly, the ability to extract and process information automatically. It is difficult to conceive modern health care practices without digital imaging and electronic health records. They both have led to a significant improvement in health care quality, but at the expense of lower physician productivity. In the words of Michael Abramoff,<sup>1</sup> a leading specialist in the field, “health-care automation has made physicians maybe do better, but not more.” However, this seems to be merely the beginning of what is possible. A general lack of resources alongside ever-increasing health care costs is bound to stagnate this impetus for further improving the quality of health care, or most likely continue to leave an incredible amount of patients undiagnosed or untreated. In the long term, this translates into further increases in health care expenditures because, if a patient is left untreated, the cost of medical care in advanced stages of a disease increases dramatically. This situation could be avoided by investing in proper screening mechanisms.

It is within this overwhelming context that digital image analysis techniques can be employed to overcome most of the problems associated with eye disease screening, management, and progression assessment, among others. Computer-aided diagnosis (CAD) and telemedicine use has risen as the integration of different technological efforts is aimed at overcoming these difficulties. Retinal image analysis is a continuously growing research field with newly completed results being translated into clinical use. However, there are still many barriers to overcome before a definitive successful clinical

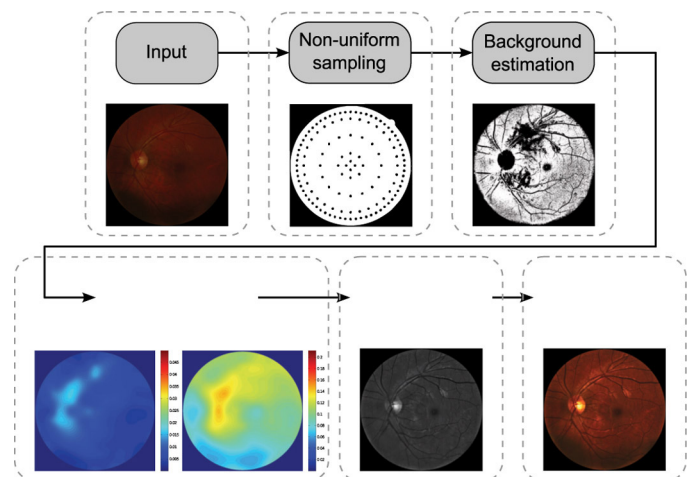


Figure 1. Illumination compensation algorithm.

deployment occurs. Retinal image illumination compensation, restoration, and change detection are only three of the many required techniques for retinal image analysis and CAD.

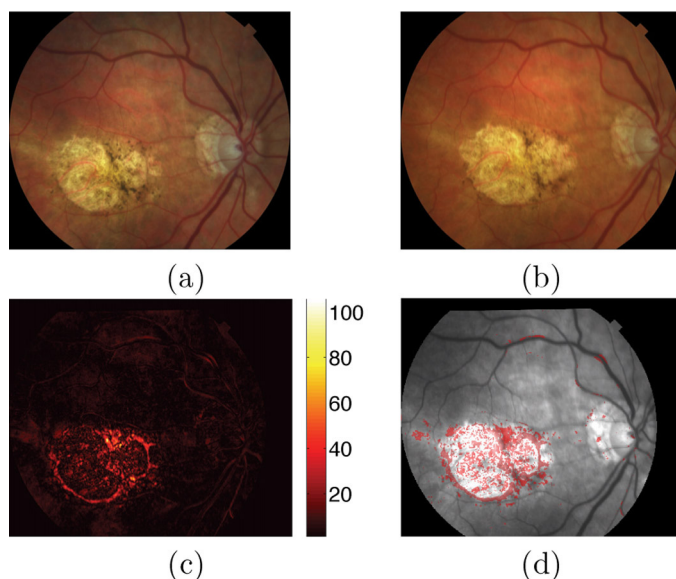
Despite controlled conditions, many retinal images suffer from non-uniform illumination, mainly due to the curved retinal surface and the geometrical configuration of the light source and camera. Several approaches have been proposed to address this topic.<sup>2</sup> They can be loosely classified into single image or multiple image compensation techniques. An example of a single-image illumination compensation algorithm is depicted in Figure 1. Our main idea is that the original degraded image can be enhanced by estimating the background luminosity and contrast distribution in order to compensate for uneven illumination.<sup>3</sup> Thus, contrast and luminosity can be understood in terms of gain and offset. Our objective is to achieve illumination uniformity by performing the inverse operations on the image. The

*Continued on next page*

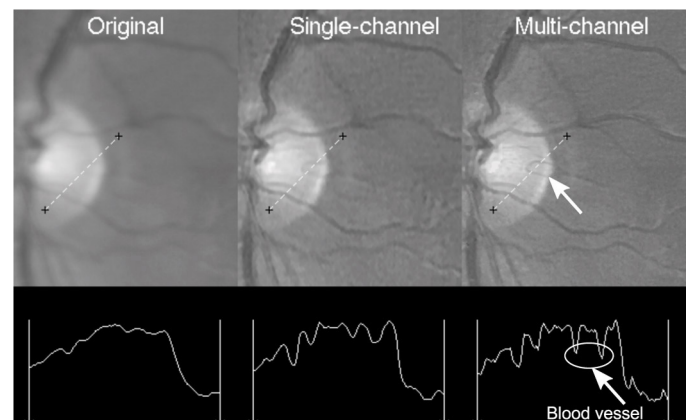
resulting image is significantly improved in terms of visibility, making it more suitable for visualization or for further processing tasks such as disease detection and segmentation.

One of the main concerns of ophthalmologists when they visually compare retinal images of the same patient over time is identifying true structural changes associated with possible pathological damage, while disregarding other changes merely caused by illumination variation or blur. To identify these changes,<sup>4</sup> we used a procedure that computed the pixel-by-pixel difference from the two registered retinal images with previous illumination compensation (see Figure 2c). From this difference image, the structural changes can be visualized and detected by taking a statistical significance test.<sup>5</sup> The two important aspects are first, that structural changes are mainly associated with a group of pixels so that the decision at a pixel is based on its neighborhood, and second, that in the absence of any change the difference is most likely given by noise. Figure 2d shows the structural changes detected from the images in Figures 2a and 2b, where most of the changes are located over the pathological region in the center.

Retinal images often suffer from blurring, which hinders their medical use. We have proposed a method for the restoration of retinal images by means of blind deconvolution (BD).<sup>4</sup> Using this method, we can recover the original scene from a single or set of blurred images in the presence of an unknown point spread function (PSF). We used a multi-image deconvolu-



**Figure 2.** Change detection. (a)–(b) Images from a patient acquired within a six-month lapse. (c) Image difference in absolute value. (d) Image change map in red on top of gray-scale retinal image.



**Figure 3.** Original degraded image, restored version using single-channel deconvolution, and multi-channel deconvolution (top, from left to right). Intensity profiles corresponding to the dashed segment (bottom).

tion algorithm,<sup>6</sup> where the PSF and the restored image are estimated in an alternation scheme and can be viewed as a Bayesian maximum a posteriori estimation of the most probable sharp image and blur kernels.<sup>4</sup> We performed the restoration with a single image and with two images to demonstrate the advantages of using multiple images (see Figure 3). The intensity profiles from the restored images reveal a noticeable enhancement with more details properly resolved. The multi-channel deconvolution overcomes the limitations of single-channel deconvolution due to information redundancy. The improvement in resolution is evidenced by the gain in contrast and steeper slopes.

Digital retinal image analysis can be effective and cost-efficient for disease management, diagnosis, and screening. The increasing need for early detection and screening, along with the ever-increasing costs of health care, are likely to be the driving forces for the rapid adoption and translation of research findings into clinical practice. Future progress in this field must focus on solving data analysis problems, such as when the amount of data to be analyzed is excessively large and when the analysis is complex and requires quantification, as opposed to the more qualitative nature of the human expert.

Our next step is to continue developing techniques for retinal image analysis, especially for longitudinal change detection and image enhancement, to aid in early disease detection.

*The authors are grateful for the support of the Spanish Ministry of Education, the Ministry of Science and Innovation, and the Czech*

*Continued on next page*

Ministry of Education.

#### Author Information

---

##### Andrés G. Marrugo and María S. Millán

Applied Optics and Image Processing Group  
Polytechnic University of Catalunya  
Barcelona, Spain

María S. Millán is a full professor and optics chair whose research involves image processing, optical technologies, and applications. She is a SPIE Fellow and member of the European Optical Society.

##### Gabriel Cristóbal and Salvador Gabarda

Institute of Optics  
Science Research Council  
Madrid, Spain

##### Michal Šorel and Filip Šroubek

Institute of Information Theory and Automation  
Academy of Sciences of the Czech Republic  
Prague, Czech Republic

#### References

1. M. D. Abramoff, *Automated detection of retinal disease: When Moore's law meets Baumol's cost disease*, **SPIE Newsroom**, 2012. doi:10.1117/2.3201202.17
2. R. Winder, P. Morrow, I. McRitchie, J. Bailie, and P. Hart, *Algorithms for digital image processing in diabetic retinopathy*, **Comput. Med. Imag. Graph.** **33** (8), pp. 608–622, 2009. doi:10.1016/j.compmedimag.2009.06.003
3. A. G. Marrugo and M. S. Millán, *Retinal image analysis: Preprocessing and feature extraction* **274** (1), p. 012039, 2011. doi:10.1088/1742-6596/274/1/012039
4. A. G. Marrugo, F. Sroubek, M. Sorel, and M. S. Millán, *Retinal image restoration by means of blind deconvolution*, **J. Biomed. Opt.** **16** (11), p. 116016, 2011. doi:10.1117/1.3652709
5. H. Narasimha-Iyer, A. Can, B. Roysam, C. Stewart, H. Tanenbaum, A. Majerovics, and H. Singh, *Robust detection and classification of longitudinal changes in color retinal fundus images for monitoring diabetic retinopathy*, **IEEE Trans. Biomed. Eng.** **53** (6), pp. 1084–1098, 2006. doi:10.1109/TBME.2005.863971
6. F. Šroubek and J. Flusser, *Multichannel blind deconvolution of spatially misaligned images*, **IEEE Trans. Image Process.** **14** (7), pp. 874–883, 2005. doi:10.1109/TIP.2005.849322